



wound care alliance UK
moving forward together

Achieving effective outcomes in patients with overgranulation

Jackie Stephen-Haynes RGN DN DipH BSc (Hons) ANP. PG DipR PGDip Ed, Masters in Clinical Nursing

Consultant Nurse and Senior Lecturer in Tissue Viability for Worcestershire Primary Care Trusts and University of Worcester.
Stourport Health centre, Worcester St, Stouport on Severn, Worcestershire. DY13 8EH
j.stephen-haynes@nhs.net

Sylvie Hampton MA BSc (Hons) DpSN RGN,

Tissue Viability Consultant, Tissue Viability Consultancy Services. Eastbourne
sylvie@tissueviability.org

Introduction

Many factors will delay wound healing (Hampton & Collins 2003), overgranulation is one of these factors that can delay the wound healing process and can lead to a chronic wound.

Chronic wounds present tremendous challenges to the healthcare team. Unlike acute wounds that usually progress neatly in a timely manner through the inflammation, proliferation and maturation phases of the healing process, chronic wounds deviate from this predictable sequence of regeneration and repair (Krasner 1995) and more recently there has been increasing evidence for the effective treatment of over-granulation.

Overcoming the problem of overgranulation is difficult for health care practitioners who need to assess the condition of the granulation tissue to achieve good clinical outcomes for patients.

In order to understand overgranulation, we must first understand the wound healing process and therefore, the aim of this booklet is to provide information on the healing process and to describe how a wound becomes chronic and colonised, providing a background to why a wound becomes over-granulated, how to avoid its occurrence and how to treat it once it is established.

Achieving effective outcomes for patients with over-granulation is possible and clinicians need the skills of assessment, differential diagnosis, knowledge of the evidence to support modern treatments and good communication skills to explain this clearly to the patient.

The wound healing process

There is a great difference between chronic wound healing and acute wound healing and they are not interchangeable. An acute wound will heal, without problems, in an orderly fashion unless the underlying pathology is not supportive of healing or the wound becomes clinically infected (Dealey 2007). The wound that does not heal in the normal way will become chronic and will then require art (knowledge and experience) and science (knowledge of research outcomes) in order to bring the wound back into the acute stage ready for healing.

The healing process associated with an acute wound is a dynamic one which can be divided into three phases (Dealey 2007):

- **Inflammation**
- **Proliferation**
- **Maturation**

Stage of Inflammation

Inflammation occurs immediately at the moment of tissue damage, lasts a few days, five at most, and is the body's natural response to injury. As soon as the injury occurs the blood vessels in the wound bed constrict and a clot is formed. Once bleeding is halted, the blood vessels then dilate to allow essential cells; antibodies, white blood cells, growth factors, enzymes and nutrients to reach the wounded area. Because the vessels have dilated, fluid (exudates) can now easily leak out into the wound bed (Enoch & Price 2004; Enoch 2006). At this stage neutrophils and macrophages commence their protective role and begin the orchestration of wound healing, moving onto proliferation and it is this stage that chronicity can be established, particularly if the wound becomes colonised or is not treated appropriately. If chronic inflammation occurs, then there is a potential for future overgranulation. Certainly, chronic inflammation will prevent the second stage (proliferation) from occurring (Moore 2004).

Stage of proliferation

The restoration of tissue and the redevelopment of tissue strength following wounding are initially achieved by the formation of a myofibroblast-reticulin matrix which eventually disappears as the healing wound ages (Forrest 1982). At this point, the wound begins to fill and the new collagen fibrin matrix is used by capillaries and cells as a 'scaffolding' to build the new tissue. This building tissue contains macrophages, fibroblast cells, and newly formed blood vessels, with a complex

collagen protein matrix. At this point, macrophages are probably the most important of the mediators of wound healing as they emit growth factors which attract fibroblasts and so initiates the next phase of wound healing.

The cells multiply within the matrix and fibroblasts in the granulation tissue “pull” on the matrix, causing the wound to contract, enabling the wound to move to the third stage - maturation. If clinical infection occurs at this point, the wound can develop a chronic inflammation and this inflammation can lead to tissue damage if it lasts too long (Midwood et al 2004) and it is this that will prevent the wound from continuing the healing process.

Although this has been simply explained here, chronicity is actually extremely complex and the subsequent chronic inflammation leads Matrix Metalloproteinases (MMPs) (which are so necessary to acute wound healing), to become a damaging force in the chronic wound and therefore, will delay wound healing even further and prevent the wound from progressing to the stage of maturation.

Stage of maturation

When granulation is achieved, the wound bed changes, becomes less ‘wet’ and less ‘bumpy’ with a smoother wound surface (figure 1). This is the final stage of wound healing and the epithelial cells can now grow into the centre of the wound and the wound fibres will contract the surface of the wound until it reaches closure. If this happens quickly there will be less scarring (Son et al 2005). The collagen that is laid down during the granulation period is now removed and replaced by a stronger collagen and the tissue beneath the scar and the scar itself, will go on remodelling for up to two years (Dealey 2007).

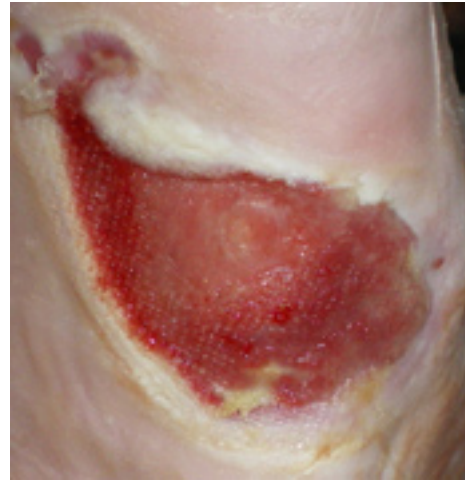

Figure 1. Granulation has smoothed out; the wound is just slightly moist and is ready for the edges to contract. The stage of healing is maturation.

These 3 stages should progress in an orderly (orchestrated) manner although the stages will overlap as can be seen in figure 2: This phase lasts 3 to 5 days

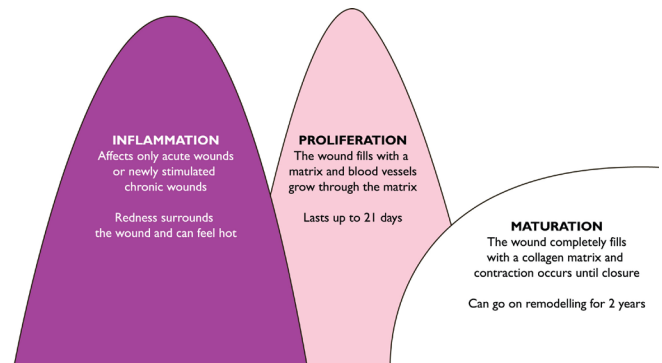


Figure 2 The 3 phases of wound healing. Each stage overlaps the previous stage and, if unable to pass from the acute phase will become chronic inflammation without healing.

If a problem, such as clinical infection occurs, then the wound can 'stick' in the 1st stage and this will then become chronic inflammation and the wound dynamics will change and the wound will halt healing.

Granulation tissue

Granulation tissue itself is composed largely of newly growing capillaries (angiogenesis) and is so called because the irregular surface is created by the capillaries looping together on the wound surface, giving the appearance of red lumps (or granules) throughout paler pink normal matrix. The appearance

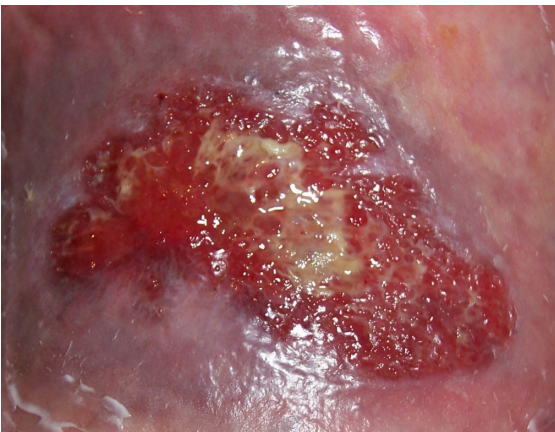


Figure 3. Granulation tissue consists of a pale base of matrix and many capillaries looping together on the surface, forming 'lumps' that have the appearance of granules.

is granular (figure 3), and naturally has the name granulation. If granulation is present in the wound it is an indication that healing is occurring and a dense network of capillaries, a high number of fibroblasts, macrophages and new formed collagen fibres will be present (Vuolo 2009).

Overgranulation

However, sometimes the granulation will 'over grow' beyond the surface of the wound and this is called 'Proud Flesh', 'hypergranulation' or 'overgranulation'. Overgranulation is defined as an excess of granulation tissue which is in excess

of required granulation tissue needed to replace the tissue deficit which often results in a peduncle (raised mass) above the wound (figure 4). It may be a difficult condition to manage and the presence of such tissue, as well as increasing the patient's risk of infection, will prevent or slow epithelial migration across the wound and thus delay wound healing (Nelsen 1999).

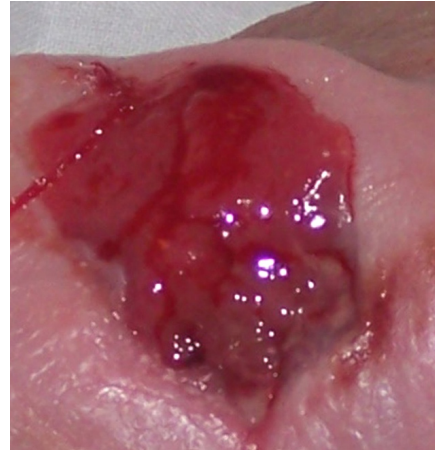

Figure 4. Overgranulation is a soft tissue that is 'proud' of the wound (Peduncle) and minus the granules that represent granulation tissue. It will not progress toward healing.

Overgranulation is also known as hypergranulation, exuberant granulation tissue, or proud flesh and usually presents in wounds healing by secondary intention. It is clinically recognised by its friable red, often shiny and soft appearance that is above the level of the surrounding skin (Johnson & Lea 2007) and can be healthy (figure 5) or unhealthy (figure 6) tissue (Harris & Rolstad 1994). There is some thought that this problem is associated with oedema of granulation tissue and this oedema may be associated with occlusive dressings that do not allow drainage of wound exudates (Vandeputte & Hoekstra 2006).

The oedema would be increased in the presence of bacterial loading in the wound, whether that loading is associated with colonisation or with clinical infection. This oedema could possibly be seen as a 'healthy' overgranulation (figure 4) which is different to 'unhealthy', infected and friable overgranulation.

However, whether healthy or unhealthy, the wound generally will not heal when the tissue is 'proud' of the wound because epithelial tissue will find it difficult to migrate across the surface and contraction will be halted at the edge of the swelling.

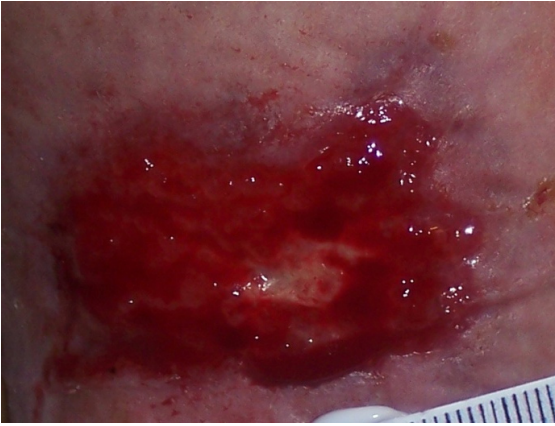

Figure 5. Healthy granulation tissue. Can be treated with pressure or topical tape (Haelan tape) steroid cream or ointment.

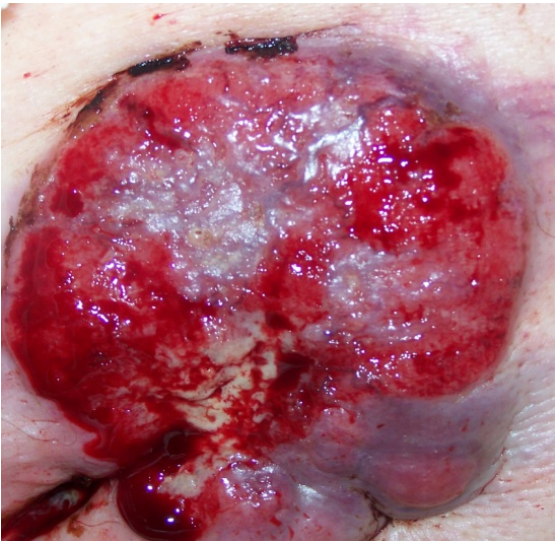

Figure 6. Unhealthy overgranulation. Extremely friable and obviously due to clinical infection, May require oral antibiotics and pressure or topical tape (Haelan tape) steroid cream or ointment.

Healthy overgranulation tissue presents as an overgrowth of moist, pinky-red tissue (figure 5) that may bleed easily (Johnson & Lea 2007) and unhealthy overgranulation tissue presents as either a dark red or a pale bluish purple uneven mass rising above the level of the surrounding skin which also bleeds very easily (figure 6). The healthy granulation tissue has the potential to reduce naturally and to eventually heal without intervention although this may take longer than if it is treated.

Particular care should be taken in differential diagnosis as an overgranulating wound can appear as similar to a malignancy wound, particularly a fungating wound (Harris & Rolstad 1994).

Overgranulation in diabetes

Soft tissue coverage of chronic diabetic ulcers can be particularly troublesome because of the lack of adequate blood supply available to the wound and this can form inadequate granulation tissue (Younes et al 2006). Also, the person with diabetes is very prone to clinical infection in wounds due to the inadequate delivery of oxygen and nutrients to the wound bed which increases the potential for abnormal tissue such as overgranulation.

Possible causes of overgranulation:

There is limited research relating to the cause of overgranulation with several authors offer several suggestions. These relate to 3 areas: inflammation, occlusion or cellular imbalance:

- **Prolonged inflammation caused by infection or dressing fibre irritant (Harris & Rolstad 1994; Nelsen 1999). Clinical infection will halt the healing process and will increase fluid loss and may contribute to overgranulation.**
- **Continued minor trauma or external friction. Reported in Gastrostomy tubes and supra pubic catheter sites (Lyon & Smith 2001; Hanlon & Heximer 1994).**
- **Over use of occlusive dressings is thought to have an influence on overgranulation as it creates a hypoxic environment that causes the body to produce more but immature blood vessels to compensate (Dealey 2007).**

- **Occlusive dressings may keep the surface of the wound extremely wet which could encourage oedema and swelling in the wound bed (Vandeputte & Hoekstra 2006).**
- **Excessive exudates, possibly due to infection or chronic colonisation, are also associated (Vandeputte & Hoekstra 2006).**
- **An imbalance between collagen synthesis and degradation due to pathology within the patient (Sussman & Bates-Jensen 2007).**

Overgranulation is extremely common in horses, as their leukocytes produce fewer mediators, initiating a weak inflammatory response, which causes the wound to become chronic. This inhibits wound contraction and gives rise to the formation of exuberant granulation tissue (Wilmink & van Weeren 2005). A question could be asked - if low numbers or inactive leucocytes produce overgranulation in horses, could it also be a cause in humans and should we be testing for white cell levels in humans with chronic wounds?

Wound assessment

Any wound assessment should include the following factors: (Stephen-Haynes 2010)

- **The environment**
- **A holistic assessment of the individual**
- **Comprehensive assessment of the wound including history, tissue, infection, peri wound area and edge of the wound**
- **Consideration of the skin as a sensory organ**
- **Assessment of the patients knowledge and understanding of their wound and general condition**

Particular assessment in relation to granulation should be to consider the most likely cause including inflammation, occlusion or cellular imbalance, as this may indicate an appropriate approach to treatment.

Malignancy

A malignancy may be mistaken for overgranulation and, if there is any suspicion that this is not normal tissue, the patient should be referred by the GP for a biopsy. There will be some clues:

- **The overgranulation has been present for many months**
- **It has a cauliflower appearance or is hard to touch**
- **It is growing outward beyond the wound margins**
- **It does not respond to any of the above treatments**

Accurate assessment is important as the removal of malignant tissue could lead to significant blood loss and would have a negative rather than a positive impact on the wound and the patient.

Treatment of overgranulation

There are many treatment options for overgranulation with limited research to support their use or to clearly suggest which is the most effective. This leads to a lack of overall consensus for treatment but broad principles for care should be considered, see Fig 7.

If the cause may be inflammation then consider securing any medical device such as gastrostomy, catheter tubing to minimise friction at the wound site.

A “wait and see” approach was suggested by Dunford (1999) but the last 11 years has seen some significant developments in this area of tissue viability and a more pro-active approach should be taken.

Inflammatory response may be related to infection and the use of an antibacterial dressing such as silver, iodine cadexomer, honey, PHMB can assist with managing local colonization and reduce the potential and also reduce the overgranulated tissue (Leak 2002). It is important that infection is identified and treated topically or systemically, depending on the spread of the infection, with care taken to avoid occlusion which will exacerbate the problem (EWMA 2006).

The earliest recommendation for treating overgranulation was foam, Harris and Rolstad (1994) reported the findings of a

prospective non-controlled correlation study with 10 patients and 12 wounds using a polyurethane foam dressing to reduce overgranulation tissue. The results demonstrated a reduction in granulation tissue ($p < 0.01$). It was concluded that the pressure of the foam on the granulation tissue reduced the oedema and flattened the overgranulation tissue. It is assumed that the pressure of the foam on the granulation tissue reduces the oedema and flattens the overgranulation tissue and, when foam dressings were advocated, it was suggested that two pieces of foam were applied to increase the pressure on the tissue (Williams 1996; Rollins 2000; Carter 2003.)

Pressure from foam was then replaced by the suggestion of double application of hydrocolloid. Controversially an occlusive dressing is thought to be a possible cause of overgranulation but potentially the pressure of the double application may reduce the excess tissue.

Morison et al (2007) notes that silver nitrate sticks are traditional practice, reducing fibroblast production. This is considered to be one of the most successful treatments for overgranulation and has produced good results in practice (Borkowski 2005). However, the use of silver nitrate directly reduces fibroblast proliferation and is therefore, not recommended for prolonged or excessive use (Dealey 2007) and should never be considered first-line therapy and should only ever be used with great care for the more stubborn area of granulation (Hampton 2007). This is particularly important as chemical burns have been reported and more likely to occur with longer application times. When it is necessary, a topical barrier preparation such as petroleum jelly or white soft paraffin should be applied to protect the normal skin surrounding the area of overgranulation (Hampton 2007).

Another highly successful method of treatment would be a short course of a topical steroid to suppress the inflammatory process (Carter 2003; Cooper 2007) and Tri-adcortyl was often the chosen steroid to be used in this case. However, it is no longer recommended for this purpose as it contains Auromycin, an antibiotic, and it is indiscriminate use of such antibiotic therapy that may have initiated MRSA. Reducing the bacterial burden with Auromycin may be one of the possible reasons

for the success of Tri-adcortyl in reducing overgranulation as reducing the bacteria load would remove the infection that stimulated the tissue to overgrow while the steroid reduces the inflammation that also stimulates overgrowth.

Lloyd-Jones (2006) reported resolution of overgranulation tissue using a silver hydrofibre dressing, but this took some weeks to resolve which is much longer than other treatments. The author does, however, pose the question of whether the most appropriate silver dressing product was used in this study and if the use of silver products on overgranulation tissue is appropriate. With the length of time the overgranulation tissue took to resolve it could be argued that the same result would have been achieved without any intervention or it may have been the pressure from the outer dressing that resolved the overgranulation.

Haelan cream/Harlan tape

Haelan tape is a transparent, plastic surgical tape (Blenderm; 3M Healthcare, Loughborough), impregnated with 4 mg/cm² fludroxycortide (flurandrenolone), which allows steady distribution of the steroid to the affected site. Fludroxycortide is a fluorinated, synthetic, moderately potent corticosteroid. As with other topical steroids, the therapeutic effect is primarily the result of its anti-inflammatory, antimitotic and antisynthetic activities.

An advantage of the steroid in a tape form is the capacity to cut the tape to fit around tubes, e.g. percutaneous endoscopic gastrostomy (PEG) tubes and supra-pubic catheters. Additionally, the pressure exerted by the tape while in situ may have a positive effect on the reduction of overgranulation tissue. Importantly, the resolution was noted within 7 days or less by Johnson (2007) who reported successful outcomes in 7 patients including post surgery, a lymphocele, dehisced abdominal wounds, venous leg ulceration, PEG and supra-pubic catheter sites. Similarly, Oldfield (2009) reports successful treatment of an overgranulated surgical wound, tracheostomy site, diabetic foot ulcer, peg insertion site and a stoma site. Importantly, corticosteroids whilst fast acting is not licensed for use on open wounds. Haelan tape contains a low dose of steroid and is marketed specifically for the purpose of overgranulation.

Removal of overgranulation

Because granulation tissue is very delicate, it can sometimes be removed by wiping with a cotton swab. However, this should only be undertaken by a nurse experienced in wound care such as a Tissue Viability Nurse, as the wound could be traumatised and healing could be further delayed. Surgical or conservative shape wound debridement is an option, however, this should only be undertaken by a surgeon as it will be cutting into live tissue with a blood supply and could cause a clinical infection to occur.

Increased pressure

Extra pressure application using compression bandaging or firm fixation tape may help. However, this should be monitored closely and if changes are not seen within a week, one of the above solutions should be considered. However, there is no literature to back up many of the above claims and the advice is often based on anecdotal and expert opinion. Also, with time, healthy overgranulation may resolve itself without intervention and the tissue only needs to be removed if epithelialisation is retarded and healing is impeded because the skin surface will be restored during the remodelling or the maturation stage of healing (Moore 2004).

Suggested treatment for overgranulation (Fig. 7)

Treatment options	Treatment objective	Evidence base
Wait and see	Over-granulation may be transient	Dunford (1999)
Apply a foam dressing	To flatten and absorb moisture	Harris & Rolstad, (1994) Williams (1996) Rollins (2000) Carter (2003)
Change from an occlusive to a non-occlusive dressing;	To reduce moisture	Carter 2003
Apply double hydrocolloid	Despite its recommendation its effect is debatable	Anecdotal
Topical corticosteroid	Reduce the cell division and production of granulation tissue	Carter (2003) Cooper (2007)
Silver nitrate pencil	Only if all else has been ineffective	Morison et al (2007) Borkowski (2005)
Foam and silver	Antimicrobial and compression from the foam	Lloyd Jones (2006)
Surgical excision	Undertaken in theatre as very last resort	
Haelan cream / Haelan tape		Johnson (2007) Oldfield (2009)

Prevention of overgranulation

Overgranulation is certainly recognised as a clinical problem (Harris & Rolstad (1994), Williams (2006), Dealey (2007), Vuolo (2009) and most clinicians feel the need to remove the excess tissue. However, the limited evidence regarding the management of overgranulation tissue necessitate a level of clinical judgement for the management of each individual patient to ensure that removal of the tissue is not actually harmful. If the tissue is healthy or if it is malignant, removal of the tissue could cause harm and should be avoided. However, if the tissue is unhealthy overgranulation, not removing it will place the patient at increased risk of clinical infection. The simplest rule would be to use occlusion (if it is a cause), short term only, providing protection, warmth and a hypoxic environment in the early stages at a time that is most required. Once granulation is established, a less occlusive dressing could be selected.

Another cause is thought to be infection (EWMA 2006), therefore precautionary measures should be undertaken to ensure the wound does not become chronically colonised or infected.

The most successful method of prevention would be appropriate assessment and treatment of the wound, ensuring that the chronic wound is taken back to an acute wound where healing will occur and then clever selection of dressings that will prevent colonisation. Continued assessment will alert the nurse to changes in the granulation status and immediate action will ensure that overgranulation does not become a problem.

Conclusion

Overgranulation is a common problem encountered in wound care. There are several potential options for treatment. Some have an immediate short term effect but may have a longer term unfavourable effect e.g. silver nitrate application and surgical excision, which may delay wound healing by reverting the wound back to the inflammatory phase of healing. Other products, such as foams and silver dressings may offer some effect but have frequently been utilised as a long term treatment, without clinical benefit. The more recent research supporting Haelan cream and tape indicates is an efficacious and costeffective treatment for overgranulation in a variety of wound types. The future of treating overgranulation may lie with surgical lasers since lasers can not only remove overgranulation tissue but will also cauterize small blood vessels and are very selective, leaving healing cells alone while removing excess and unhealthy tissue.

Notwithstanding, further research is required to establish exactly why overgranulation occurs as the cause will indicate the most appropriate prevention and treatment.

The ability of the healthcare practitioners to assess and differentiate between healthy and unhealthy overgranulation is essential in making informed clinical decisions on how to achieve effective outcomes. In conclusion, the clinician should not be concerned about overgranulation as it can be treated if it cannot be prevented.

References

- Bates-Jenson, B (1997) *Wound care products: A guide to choice*. Nursing Homes (USA). November/December pp.47-54.
- Borkowski, L (2005) *G tube care: managing hypergranulation tissue*. Nursing. Aug; 35(8):24
- Carter, K (2003) *Treating and managing pilonidal sinus disease* Journal of Community Nursing July 17 (7) 28-33
- Cooper, R (2007) *Steroid therapy in wound healing*. Free Paper. EWMA Conference. Glasgow.
- Dealey, C (2007) *The Care of Wounds: a guide for nurses 3rd edition*. Wiley-Blackwell, Oxford. 1999
- Enoch, S., Price, P (2004) *Cellular, molecular and biochemical differences in the pathophysiology of healing between acute wounds, chronic wounds and wounds in the aged*. www.worldwidewounds. Accessed 7.3.2010
- Enoch, S (2006) *ABC of wound healing: Wound assessment* BMJ; 14(89) - 132 March ISSN 0966-6494
- Dunford, C (1999) *Overgranulation tissue*. Journal of Woundcare. 8 (10) p506-7
- EWMA (2006) *Position document. Management of infection*. London. MEP Ltd 2006. Topical management of infected grade 3 & 4 pressure ulcers.
- Moore, Z & Romanelli, M. p11-13
- Forrest, L (1982) *Current concepts in soft connective tissue wound healing*. British Journal of Surgery 70(3) 133-140.
- Hampton, S., Collins, F (2003) *Tissue Viability a comprehensive guide*. Whurr publications. London.
- Hampton, S (2007) *Understanding overgranulation in tissue viability practice*. British Journal of Community Nursing, September 2007, vol.11. 12/9(S24-30), 1462-4753
- Hanlon, M., Heximer, B (1994) *Excess granulation tissue around a gastrostomy tube exit site with peritubular skin irritation*. Journal Wound Ostomy Continence Nursing 21(2) p76-77
- Harris, A., Rolstad, B. S (1994) *Hypergranulation tissue: a non-traumatic method of management*. Ostomy Wound Management 40 (5): 20-30
- Johnson, S (2007) *Haelan Tape for the treatment of overgranulation tissue*. Wounds UK. Vol 3 Issue 3 http://www.wounds-uk.com/journal/0303_haelan_article.shtml. Accessed 7.3.2010
- Johnson, S., Lea, K (2007) *Overgranulation tissue, a new approach* www.woundsuk.co.uk/downloads/.../JohnsonSusanPosterformatted.doc (accessed 12th January 2010).
- Krasner, D (1995) *Minimizing factors that impair wound healing: a nursing approach*. Ostomy Wound Management. Jan-Feb; 41(1):22-6, 28, 30; quiz 31-2..
- Leak, K (2002) *PEG site infections: a novel use for Actisorb Silver 220 (562kb)* British Journal of Community Nursing, 7(6), 14 Jun, pp 321 – 325
- Lloyd-Jones, M (2006) *Treating Overgranulation with a silver hydrofibre dressing*. Wound Essentials 1: 116–8
- Lyon, C., Smith, A.J (2001) *Abdominal Stomas and Their Skin Disorders – An Atlas of Diagnosis and Management*. Martin Dunitz Ltd, London
- Midwood, K.S., Williams, L.V., Schwarzbauer, J.E (2004) *Tissue repair and the dynamics of the extracellular matrix*. The International Journal of Biochemistry & Cell Biology, 36(6): 1031-1037

Disclaimer: The views expressed in this document are those of the author(s) and not necessarily of the Wound Care Alliance UK.